THE BLOOD SUPPLY OF NEOPLASMS IN THE LIVER *

CHARLES BREEDIS, M.D., and GANG YOUNG, M.D.

(From the Department of Pathology, University of Pennsylvania School of Medicine, Philadelphia, Pa., and the Pathology Research Institute, Medical College, National Sun Yat Sen University, Canton, China)

During an investigation of the hepatic circulation in rabbits, we noted that hepatic tumors failed to stain when India ink was injected into the portal vein, whereas hepatic tissue between the tumors became intensely black.[1] However, when the hepatic artery was injected the tumors as well as the liver tissue became stained. It seemed, therefore, that the tumors were supplied mainly, perhaps exclusively, by arterial blood, in contrast to the predominantly portal supply of hepatic tissue.[2]

In the experiments to be reported, the blood supply of a variety of neoplasms growing in the liver of several species was estimated by various injection methods. Evidence is presented to show that the blood supplying all malignant neoplasms tested was largely, if not exclusively, arterial. A preliminary summary of some of these findings has been reported.[3]

MATERIALS AND METHODS

All determinations of blood supply were based on the results of injection of colloidal pigments prepared essentially as given by Cowdry,[4] with the modifications to be described.

India ink (Higgins Waterproof) was diluted with an equal volume of distilled water just prior to use, or was used undiluted. *Carmine* (Coleman and Bell), 75 gm. in 1000 ml. of distilled water, was shaken for 15 minutes by hand or agitated for 5 minutes in a Waring blendor to form an opaque colloidal solution. *Gelatin* (Bacto-gelatin, Difco), 80 gm. dissolved in 1000 ml. of distilled water at 100° C. and then cooled to 40° C., was added to the carmine solution. *Prussian blue* (Tieman's Soluble Blue, Coleman and Bell), 100 gm. in 1000 ml. of distilled water, was shaken by hand for 10 minutes and then added slowly with stirring to 1000 ml. of gelatin solution as previously prepared. The sediment, after a few days at 37° C., was discarded. The supernatant could then be forced through the finest capillaries. Gelation of the solutions tended to occur at room temperature. Prior to use they were heated to 60° to 80° C. and then cooled to 30° to 40° C. With a few thymol crystals as preservative, both solutions remained stable for months.

* This investigation was supported in part by a research grant (C-1116) from the National Cancer Institute, of the National Institutes of Health, Public Health Service.

Received for publication, February 8, 1954.

In *living* rabbits with hepatic tumors, India ink was used to trace the flow of portal venous and hepatic arterial blood. Under ether anesthesia a midline abdominal incision was made, exposing the liver and adjacent viscera. India ink in amounts of 2 to 5 ml. was injected into either the hepatic artery or a large tributary of the portal vein. The period of injection was 5 to 10 seconds. Immediately after injection the chest was opened rapidly and the heart incised to prevent circulation of ink.

Living etherized mice were given injections into the portal vein in a similar manner, using 0.1 to 0.2 ml. of ink over a period of 2 to 5 seconds. The hepatic artery was too small to be injected by this method.

Tumor-bearing livers of animals or of human subjects at necropsy were injected by means of an infusion apparatus (Fig. 4) with which it was possible to wash out hepatic artery and portal vein simultaneously with physiologic salt solutions at different pressures, and then switch to the carmine and Prussian blue solutions at these pressures. However, since neither preliminary washing nor maintenance of a physiologic ratio between arterial and venous injection pressure was found to be important, both procedures were soon abandoned. Injections were performed at pressures of 80 to 150 mm. of Hg. When artery and vein were injected simultaneously, the pressure was usually kept the same in both vessels.

The hepatic artery of necropsied mice was too small to be injected directly. The needle was inserted into the aorta just below the celiac artery. Injection was performed with the opening of the needle at the level of the celiac artery. The aorta was ligated above and below this point.

In all specimens injection was continued until the pigments flowed from the hepatic vein. This usually required 5 to 10 minutes. All external vessels were then clamped or ligated, and the entire liver was fixed in 20 per cent formalin for dissection. Livers from human necropsy cases, because of their large size, were placed in ice-cold 20 per cent formalin for several hours in order to gel the injection masses completely. They were then cut into slices 1 to 2 cm. thick and allowed to fix at room temperature.

The degree of staining of the liver surface and of visible tumors was noted throughout the period of injection. After fixation the liver was sliced and the freshly cut surfaces examined under a dissecting microscope. In microscopic sections lightly counterstained with hematoxylin, the injected pigments were seen to be localized within vessels of all calibers.

For the preparation of corrosion specimens, the injection mass was made by dissolving sheet vinylite in a mixture of equal parts of acetone and amyl acetate, to a concentration of 8 per cent. Sudan III or Oil Blue BNA were used to color the mass. After injection the specimen was left in several changes of 95 per cent alcohol in order to extract the amyl acetate. The regions to be studied were then cut out and corroded in concentrated HCl.

Results

Neoplasms Experimentally Induced in the Liver

Tumors were produced by injecting suspensions of tumor cells into the portal vein, hepatic artery, or liver parenchyma of rabbits, and the portal vein or liver parenchyma of mice.

The Vx2 strain[5,6] of carcinoma of rabbits* has been maintained by transplantation into the muscles of the hind leg of rabbits. For the present experiments, actively growing tumor was squeezed through a 40-mesh stainless steel sieve into Ringer-Tyrode solution to form a suspension of single cells and small particles. Through a midline abdominal incision, etherized rabbits were given injections of 0.2 to 0.5 ml. of suspension into either the hepatic artery, portal vein, or liver parenchyma.

A strain of methylcholanthrene-induced spindle cell sarcoma of mice has been maintained by serial subcutaneous inoculation. Suspensions of this tumor, prepared as previously stated, were injected through a 27-gauge needle into either a large tributary of the portal vein or the liver itself, in amounts of 0.05 to 0.15 ml.

Rabbits were sacrificed 3 to 8 weeks after inoculation, mice in 2 to 4 weeks, and their livers injected with the colloidal dyes.

Table I shows the conclusions drawn from the results of the injections. It is evident from the table that the blood supply of the hepatic tumors was not determined by the route through which tumor emboli reached the liver. The supply was arterial, whether emboli were injected into the hepatic artery or the portal vein, and also arterial when tumor was injected directly into the liver parenchyma.

In one half of the animals shown in Table I the colloidal pigments were injected into both hepatic artery and portal vein; the other half received pigment only in the portal vein. In other animals, not shown in the table, the patency of tumor vessels was demonstrated repeatedly by means of arterially injected pigments.

* Obtained from the laboratory of Dr. John G. Kidd, Department of Pathology, Cornell University Medical College, New York City.

The gross appearance of liver injected with pigment through the portal vein, whether during life or after death, is illustrated in Figure 1. The liver takes on the color of the pigment, whereas the tumors remain uncolored. In contrast, pigment injected into the hepatic artery (Fig. 2) colors chiefly the tumors and hepatic tissue adjacent to them. The microscopic appearance of such injected livers is shown in Figures 7, 8, and 9.

The question arose: How is the portal blood flow through tumor-bearing regions of liver eliminated? Microscopic sections showed nu-

TABLE I

Blood Supply of Neoplasms Inoculated into the Livers of Rabbits and Mice by Various Routes

Site of injection of tumor cell suspension	Number of animals		Blood supply of tumors*	
	Rabbits	Mice	Hepatic artery	Portal vein
			%	%
Hepatic artery	4	0	100	0†
Portal vein	6	1	100	0†
Liver parenchyma	1	1	100	0

* The blood supply was determined by the number of vessels per low-power field that were filled by the respective arterial and portal injection masses.

† A small portal blood supply was noted in one rabbit tumor of the several hundred examined.

merous branches of the portal vein, of all sizes, in process of occlusion by invading tumor cells. These changes are illustrated in Figures 10 and 12. Completely occluded portal branches could be distinguished some distance within the tumor. No evidence of occlusion or invasion of arterial branches was seen.

Microscopic examination showed also that many tributaries of the hepatic vein, at the edge of a growing tumor, were invaded or occluded by tumor cells (Fig. 11). The results of retrograde injection of pigment into the hepatic vein indicate that this process of occlusion tends to become complete. In 4 rabbits so injected, although the pigment rapidly traversed the hepatic vessels and appeared in the portal vein, only a few vessels of the tumors were injected. These were small and near the surface of the tumors.

Corrosion preparations made after injecting colored vinylite into the hepatic artery and portal vein indicate that the vasculature of the tumors is very scanty as compared to that of the surrounding liver. In the preparations illustrated in Figures 5 and 6 the tumors appear as "holes" in the rich network of hepatic vessels.

Neoplasms Metastatic to the Liver

Human. Thirteen livers with metastatic carcinomas found at necropsy were injected by the methods which have been described. The blood supply of the tumors was shown to be predominantly or exclusively arterial. The results of injection of the livers of 11 of these subjects are shown in Table II.

TABLE II

Blood Supply of Neoplasms Metastatic to the Liver Found in Eleven Human Subjects at Necropsy

Primary tumor	Approximate number of metastases examined	Size of metastases	Blood supply of tumors*	
			Hepatic artery	Portal vein
		mm.	%	%
Adenocarcinoma, breast	300	10–30	80	20
Undifferentiated carcinoma, breast	50	1–10	95	5
Adenocarcinoma, bronchus	200	2–35	100	0
Adenocarcinoma, bronchus	500	2–50	100	0
Undifferentiated carcinoma, kidney	200	2–35	95	5
Squamous cell carcinoma, cervix	10	20–50	100	0
Adenocarcinoma, sigmoid	10	0.5–1	80	20
Adenocarcinoma, sigmoid	10	1–3	100	0
Adenocarcinoma, stomach	50	2–100	100	0
Adenocarcinoma, rectum	2	15 and 50	95	5
Adenocarcinoma, colon	1	7	100	0

* The blood supply was estimated by determining the number of vessels per low-power field that were filled by the respective arterial and portal injection masses.

Interpretation was sometimes difficult with human necropsy material because of varying degrees of post-mortem autolysis and intravascular clotting. Nevertheless, in only 2 cases was autolysis sufficient to allow some leakage of pigment through capillary endothelium into tissue spaces. Because of scattered blocking of vessels by clots, it was necessary to eliminate from the series all tumors occurring in regions of the liver not reached by both injection masses.

Retrograde injection through the hepatic vein was done in 3 cases, in 2 of which the hepatic artery was also injected and in one the portal vein. All showed only very slight penetration of the injection mass in the hepatic vein into tumor vessels, and these were located near the surface of the tumor. Similar results were obtained with the portal mass. The arterial mass, however, penetrated vessels throughout the tumors.

Microscopically, occlusion of portal branches due to invasion by growing tumor cells was found in some of the metastatic tumors and was similar to that seen in the experimental tumors. In addition, the 3 livers injected through the hepatic vein showed invasion and blockage of tributaries of this vessel by tumor cells.

One *leopard frog* having 5 liver metastases from a primary adenocarcinoma of the kidney[7] was studied. Carmine injected into the portal vein produced intense red staining of all liver sinusoids. The tumors remained colorless except for a few lightly colored vessels in one of the smaller tumors.

Neoplasms Primary in the Liver

Five rats having primary hepatomas and cholangiomas induced by feeding p-dimethyl-amino-azobenzene* were killed with ether and injected immediately with carmine and Prussian blue as has been described. Each liver had two or more white tumor masses, 3 to 25 mm. in diameter, that had the gross and microscopic appearance of malignant growths. Only such tumors are considered in the results shown in Table III.

TABLE III

Blood Supply of Primary Liver Tumors and Surrounding Cirrhotic Liver in Five Rats Fed p-Dimethyl-amino-azobenzene

Type of tissue	Number of animals	Blood supply of tissue*	
		Hepatic artery	Portal vein
		%	%
Liver cell carcinoma (hepatoma)	1	85	15
Liver cell carcinoma (hepatoma)	4	100	0
Bile duct carcinoma	2	100	0
Mixed liver cell and bile duct carcinoma	3	100	0
Cirrhotic (scar) tissue	5	90	10
Nodules of regenerating liver	5	40	60

* The blood supply was estimated by determining the number of vessels per low-power field that were filled by the respective arterial and portal injection masses.

It can be seen from Table III that only liver cell carcinomas retained some portal blood supply. Usually this was small. Bile duct carcinomas and mixed carcinomas were supplied entirely by the hepatic artery.

Rats fed p-dimethyl-amino-azobenzene develop severe cirrhosis with

* Obtained from the laboratories of Dr. Julius White and Dr. Harold Stewart of the National Cancer Institute.

large nodules of regenerating liver cells. These nodules, like regenerating liver, had a predominantly portal supply. In contrast, the abundant, dense, white scar tissue between the regenerating nodules was supplied entirely by the hepatic artery. Many of the scarred regions contained islands of hyperplastic bile ducts. An additional rat fed p-dimethyl-amino-azobenzene had severe cirrhosis but no neoplastic growths. It was injected with carmine through the hepatic vein. All regions of this liver, including scars, stained bright red quickly and uniformly, indicating that scarred areas, in contrast to tumors, have adequate venous drainage.

Miscellaneous Benign or Non-Neoplastic Lesions of the Liver

During the course of the previous experiments, 5 cases having benign or non-neoplastic lesions in the liver were encountered, in addition to the rats showing cirrhotic scarring. Injections were performed soon after death, using the same methods as for malignant lesions.

Three hemangiomas in a human subject had a mixed blood supply. These lesions, grossly and microscopically benign, consisted of numerous dilated blood channels apparently having connections with both hepatic artery and portal vein. On the other hand, scar tissue in the rabbit, mouse, and rat, and foreign body granulomas in the mouse, were supplied chiefly or entirely by the hepatic artery.

Discussion

Results similar to those reported here were obtained by Wright[8] on livers from human necropsy cases showing cirrhosis and metastatic cancers. Wright further concluded that the main venous drainage from the cancers was into the portal rather than the hepatic veins. This interpretation could not be made from the present experiments.

According to Willis,[9] most carcinomas metastasizing to the liver from the alimentary tract reach this organ via the portal vein. However, the results obtained in rabbits suggest that in man emboli reaching the liver via the hepatic artery could become established and that their blood supply would then be the same as in tumors arriving via the portal vein.

Does the arterial supply of tumors indicate that neoplasms stimulate only the proliferation of vessels of an arterial type in the formation of tumor stroma? If this were the case, tumors in the lung should be supplied by the bronchial rather than the pulmonary artery, since the latter carries venous blood. Wright[10] found only bronchial arterial proliferation in tumors of the lung studied at necropsy. Others,[11,12]

also using human material, have concluded that primary (bronchogenic) carcinomas are supplied by the bronchial artery only, whereas metastatic tumors receive blood from the pulmonary artery as well. Our own results[13] with rabbits support the last conclusion. The problem requires further study by refined injection methods.

One additional organ, the amphibian kidney, has a dual blood supply. It would be of interest to determine whether renal carcinoma of the leopard frog,[7] a fairly common neoplasm, is supplied by the renal artery, the renal portal vein, or both.

In the liver the experimental results can be largely accounted for by the well known ability of neoplasms to invade veins. Arteries are rarely invaded.[14] Branches of the portal vein as well as tributaries of the hepatic vein are progressively invaded and obliterated, so that the tumor becomes white and bloodless. This relative avascularity of a number of neoplasms has recently been confirmed by means of radioiron.[15] Only the arteries tend to persist. Blood pumped into the neoplasm escapes by devious, as yet unobliterated, channels to its periphery.

There are several practical considerations based upon the reported findings: (1) In the absence of knowledge concerning the vasculature of hepatic tumors, one might mistakenly think them to be well situated for chemotherapy by mouth, since blood from the intestine goes directly to the liver. Actually, of course, this blood would by-pass the neoplasms and would reach them only after recirculation. (2) Would ligation of the hepatic artery cause the regression of hepatic neoplasms by cutting off their blood supply? This possibility was tested in a small series of rabbits having Vx2 carcinoma. Regression did not occur. However, liver has a collateral arterial supply derived from diaphragmatic and other vessels, so that the arterial supply to the neoplasms was not completely eliminated.

Summary and Conclusions

By means of injection experiments it was shown that malignant neoplasms growing in the liver tend to acquire an exclusively arterial blood supply.

The neoplasms tested were as follows: Vx2 carcinoma of rabbits, T-241 sarcoma of mice, a variety of metastatic carcinomas found at necropsy in human cases, metastases of spontaneous carcinoma of the kidney of the frog, and primary hepatomas and cholangiomas of rats induced by p-dimethyl-amino-azobenzene.

The blood supply of transplanted rabbit and mouse tumors was

arterial, whether inoculations had been made into the hepatic artery or portal vein or directly into the hepatic parenchyma.

Much if not all of the failure of portal blood to supply tumors growing in the liver is due to progressive invasion and occlusion of portal branches by tumor cells.

REFERENCES

1. Breedis, C., Young, G., and Lucké, B. Unpublished data.
2. Markowitz, J., and Rappaport, A. M. The hepatic artery. *Physiol. Rev.*, 1951, **31**, 188–204.
3. Breedis, C., and Young, B. Blood supply of neoplasms in the liver. *Federation Proc.*, 1949, **8**, 351.
4. Cowdry, E. V. Laboratory Technique in Biology and Medicine. Williams & Wilkins Co., Baltimore, 1948, ed. 2, 269 pp.
5. Kidd, J. G. The enduring partnership of a neoplastic virus and carcinoma cells. Continued increase of virus in the V2 carcinoma during propagation in virus-immune hosts. *J. Exper. Med.*, 1942, **75**, 7–20.
6. Rous, P., Kidd, J. G., and Smith, W. E. Experiments on the cause of the rabbit carcinomas derived from virus-induced papillomas. II. Loss by the Vx2 carcinoma of the power to immunize hosts against the papilloma virus. *J. Exper. Med.*, 1952, **96**, 159–174.
7. Lucké, B. Carcinoma of the kidney in the leopard frog: the occurrence and significance of metastasis. *Am. J. Cancer*, 1938, **34**, 15–30.
8. Wright, R. D. The blood supply of newly developed epithelial tissue in the liver. *J. Path. & Bact.*, 1937, **45**, 405–414.
9. Willis, R. A. The importance of venous invasion in the development of metastatic tumours in the liver. *J. Path. & Bact.*, 1930, **33**, 849–861.
10. Wright, R. D. The blood supply of abnormal tissues in the lungs. *J. Path. & Bact.*, 1938, **47**, 489–499.
11. Cudkowicz, L., and Armstrong, J. B. The blood supply of malignant pulmonary neoplasms. *Thorax*, 1953, **8**, 153–156.
12. Wood, D. A., and Miller, M. The rôle of the dual pulmonary circulation in various pathologic conditions of the lungs. *J. Thoracic Surg.*, 1937–38, **7**, 649–670.
13. Breedis, C., and Young, G. Unpublished data.
14. Willis, R. A. Pathology of Tumours. C. V. Mosby Co., St. Louis, 1948, 992 pp.
15. Storey, R. H., Wish, L., and Furth, J. Organ erythrocyte and plasma volumes of tumor-bearing mice. The oligemia of neoplasms. *Cancer Research*, 1951, **11**, 943–947.

[*Illustrations follow*]

LEGENDS FOR FIGURES

FIG. 1. Surface of the liver of a rabbit 4 weeks after the injection of a suspension of Vx2 carcinoma into the portal vein. Before the animal was sacrificed, India ink was injected into the portal vein under ether anesthesia. The tissue appears black, whereas the tumors remain white.

FIG. 2. Liver of a rabbit injected with Vx2 carcinoma as in the specimen shown in Figure 1. Before sacrificing the animal, India ink was injected into the hepatic artery under ether anesthesia. The tissue shows only scattered flecks of ink, whereas the tumors are stained black.

FIG. 3. Sectioned surface of human liver containing metastases from adenocarcinoma of the bronchus. At necropsy the portal vein was injected with Prussian blue and the hepatic artery with carmine. The patchy gray appearance of the tumors is due to variable amounts of carmine; no blue was seen in the tumors. In contrast, the surrounding tissue was stained an intense blue.

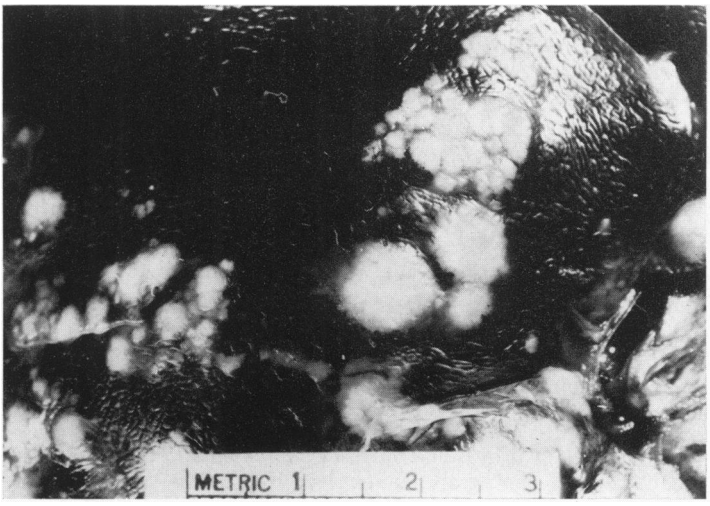

1

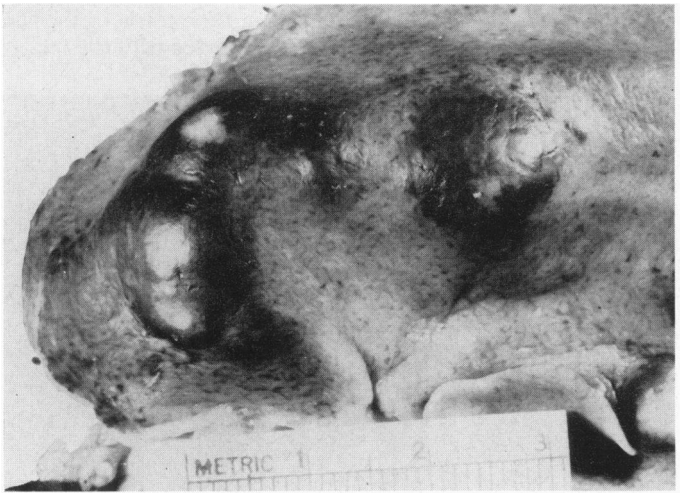

2

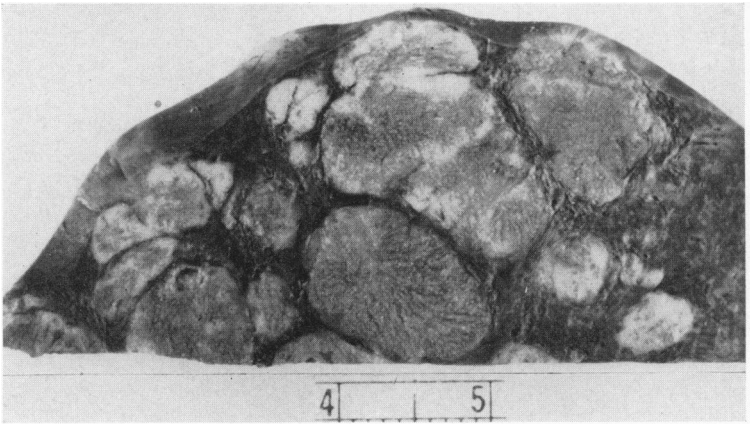

3

FIG. 4. Apparatus used for injecting artery and vein simultaneously at different pressures.

FIG. 5. Corrosion preparation showing part of the surface of the liver of a rabbit. Near the center of the photograph there is a small Vx2 tumor. Red vinylite was injected into the hepatic artery and blue vinylite into the portal vein. The red vinylite appears white in the photograph and forms a shell consisting of tiny arteries near the periphery of the tumor. The surrounding sinusoids are predominantly blue and appear gray. The gray portal branches that appear to be within the tumor are actually either below it (central part) or are overriding it (upper part). × 4.

FIG. 6. Corrosion preparation of a larger Vx2 tumor in the liver, prepared as was the specimen shown in Figure 4. Here the arteries appear black, the veins white. Near the right hand edge of the fragment there is a tumor containing many arteries, again largely confined to a shell near the periphery. There are no portal branches in the tumor. The tumor is poorly vascularized as compared to the surrounding liver. × 0.5.

FIG. 7. Section of the liver of a rabbit with Vx2 carcinoma. Tumor is shown in the upper left half of the photograph, uninvolved liver in the lower right. Immediately after sacrificing the animal, India ink was injected into the portal vein. The sinusoids contain ink, while there is none in the vessels of the tumor. The sinusoids near the periphery of the tumor are distended with the ink. × 130.

4

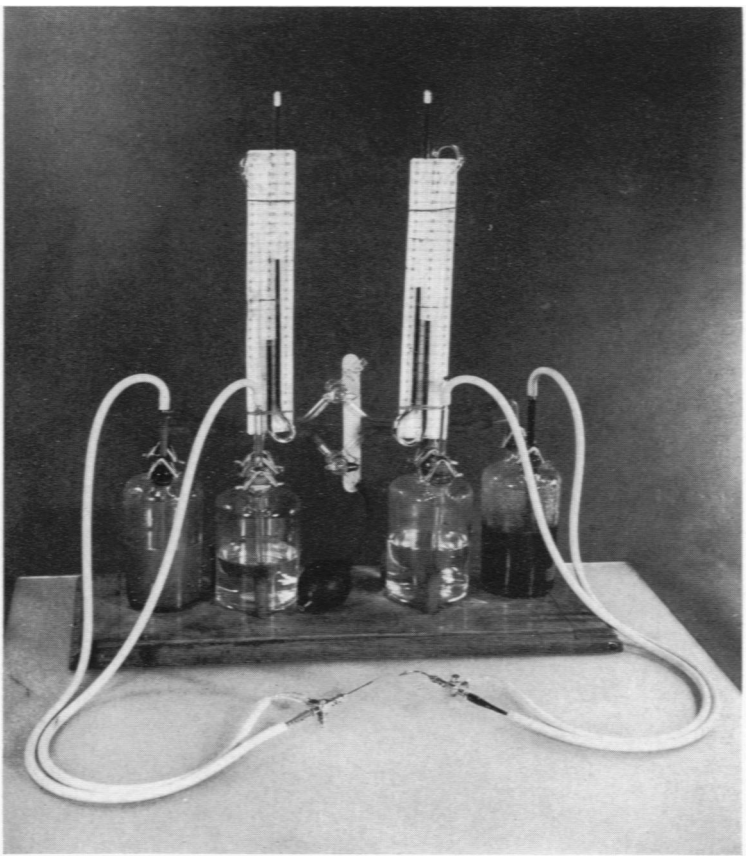

5

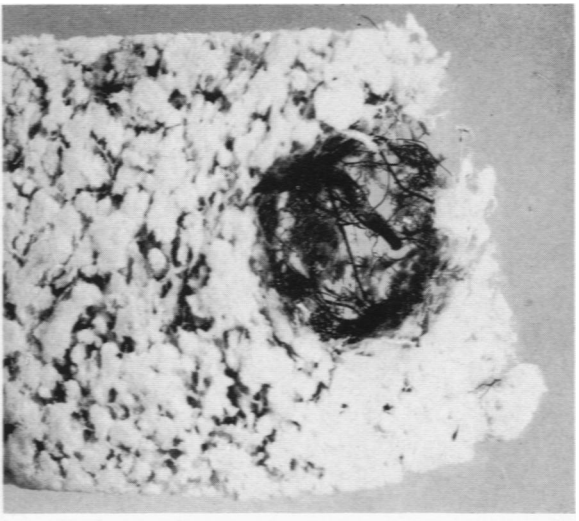

6

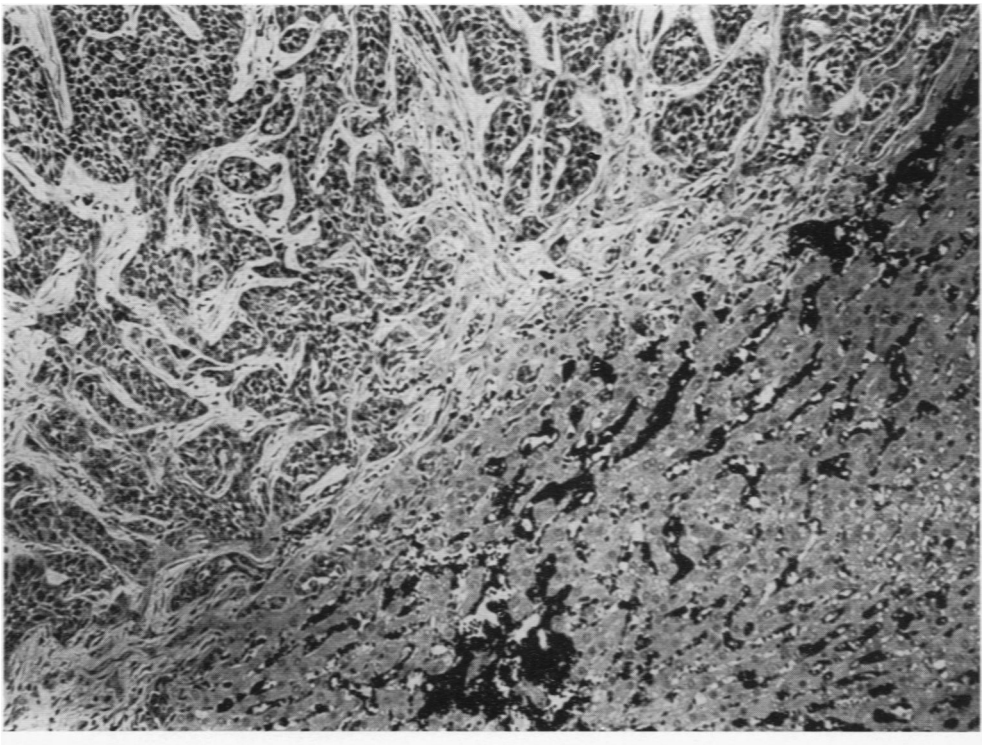

7

FIG. 8. Vx2 carcinoma in liver, prepared as described in the legend for Figure 6. Tumor is shown in the upper half of the photograph, uninvolved liver in the lower half. The sinusoids adjacent to the tumor are dilated with ink. There is none in the tumor. × 130.

FIG. 9. Vx2 carcinoma in the liver. After the animal had been sacrificed, India ink was injected into the hepatic artery. The ink fills the sinusoids of the liver (left one third of the photograph) and many vessels in the tumor. × 130.

FIG. 10. Portal space of a rabbit bearing Vx2 tumors in other parts of the liver. India ink was injected into the portal vein immediately after death of the animal. The branch of the portal vein is filled with ink, which outlines a mass of tumor cells that have grown into the vessel. × 130.

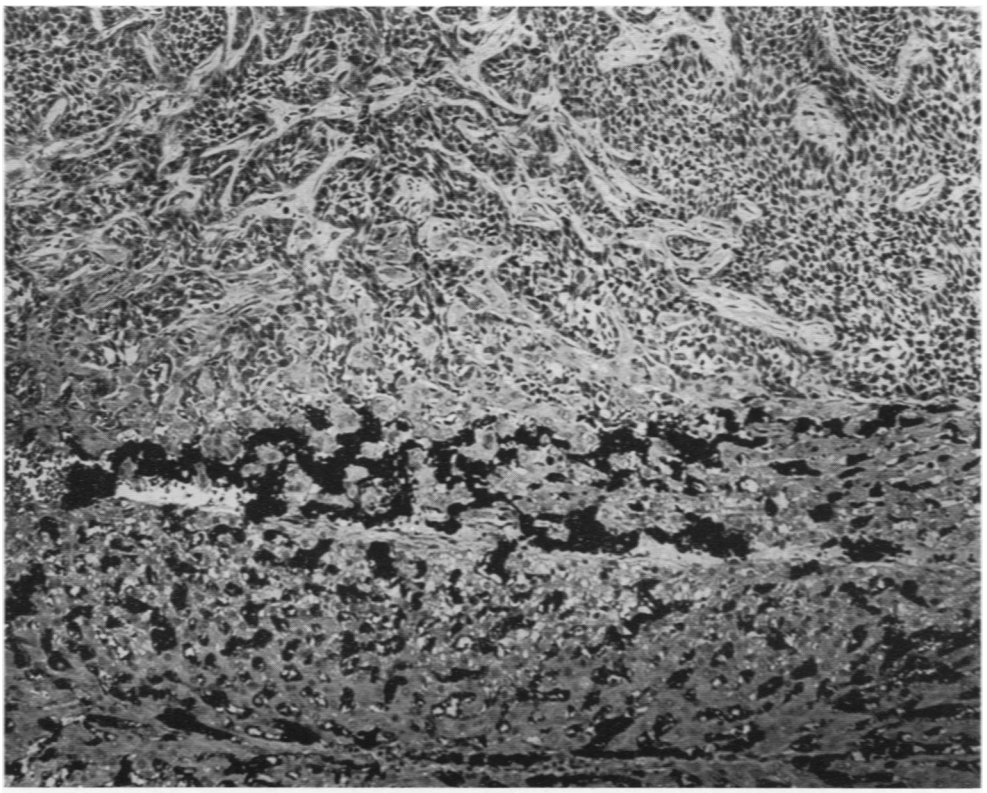

8

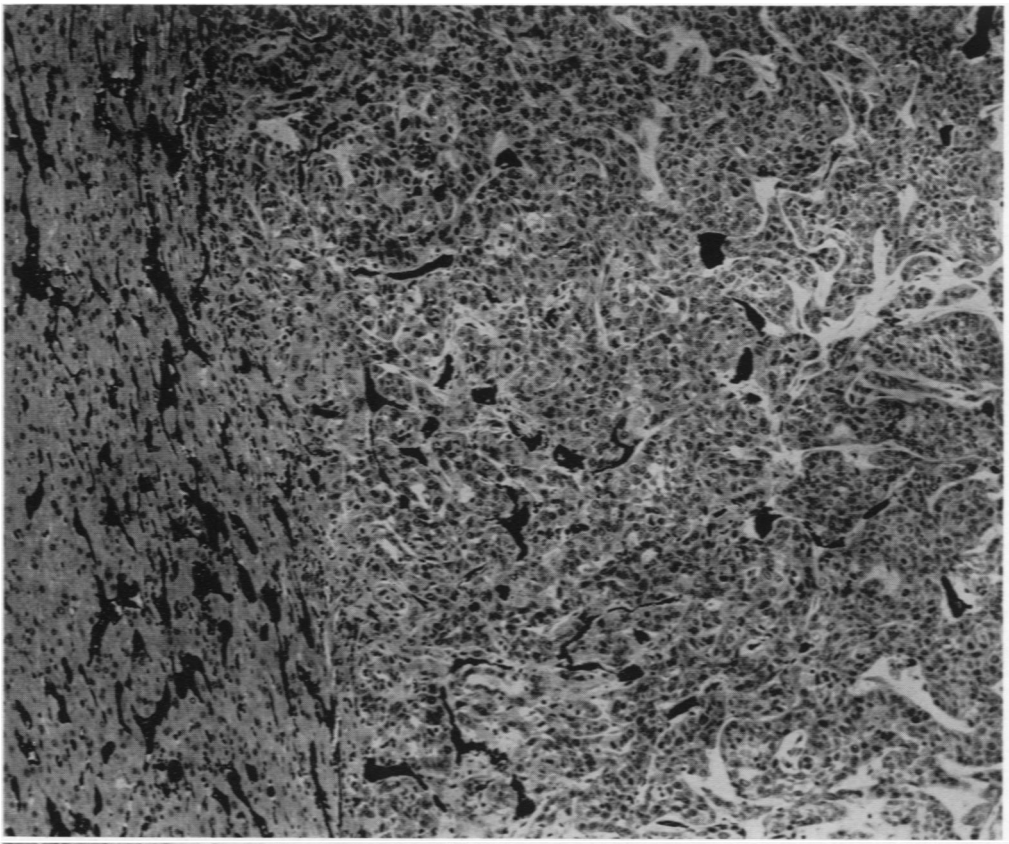

9

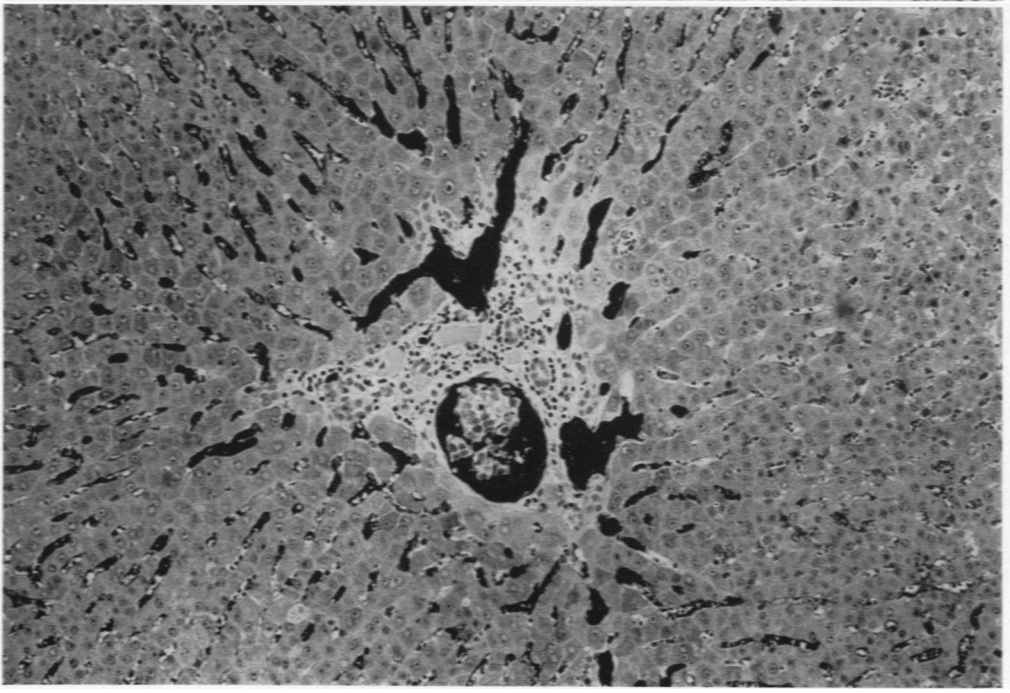

10

FIG. 11. Liver of a rabbit containing Vx2 carcinoma. Immediately after death of the animal, India ink was injected into the hepatic artery. The ink fills some vessels of the tumor (upper left-hand corner), many sinusoids, and a tributary of the hepatic vein. This vessel (center of photograph) contains a mass of tumor cells completely outlined by ink. × 130.

FIG. 12. Large branch of the portal vein in a rabbit with Vx2 carcinoma in the liver. India ink was injected into the portal vein after death of the animal. The portal branch is almost completely occluded by tumor cells, which apparently have grown in from the tumor on the left. The ink fills the remaining lumen of the portal vessel and many of the sinusoids, but not the vessels in the tumor. × 130.

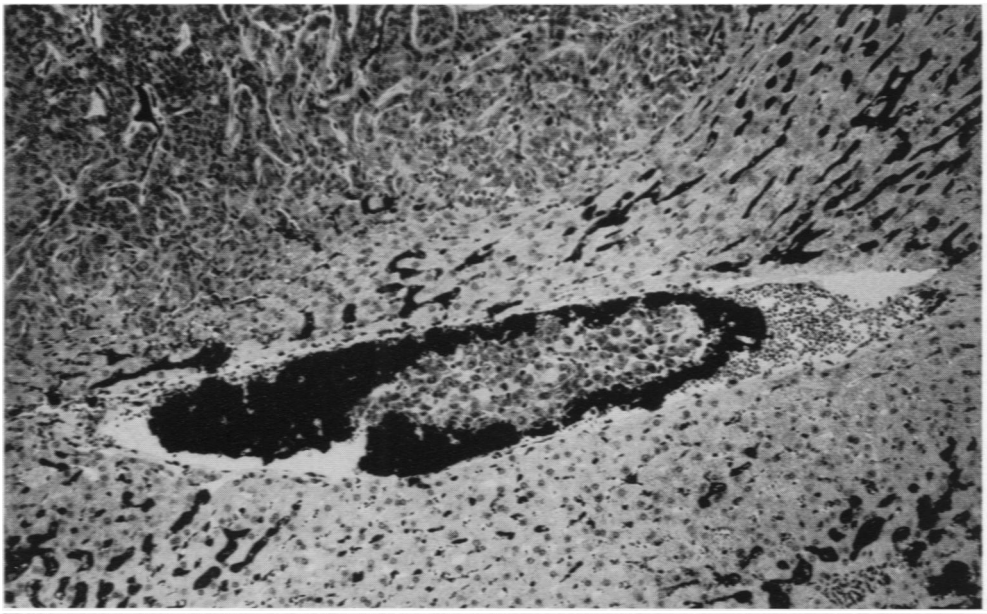

11

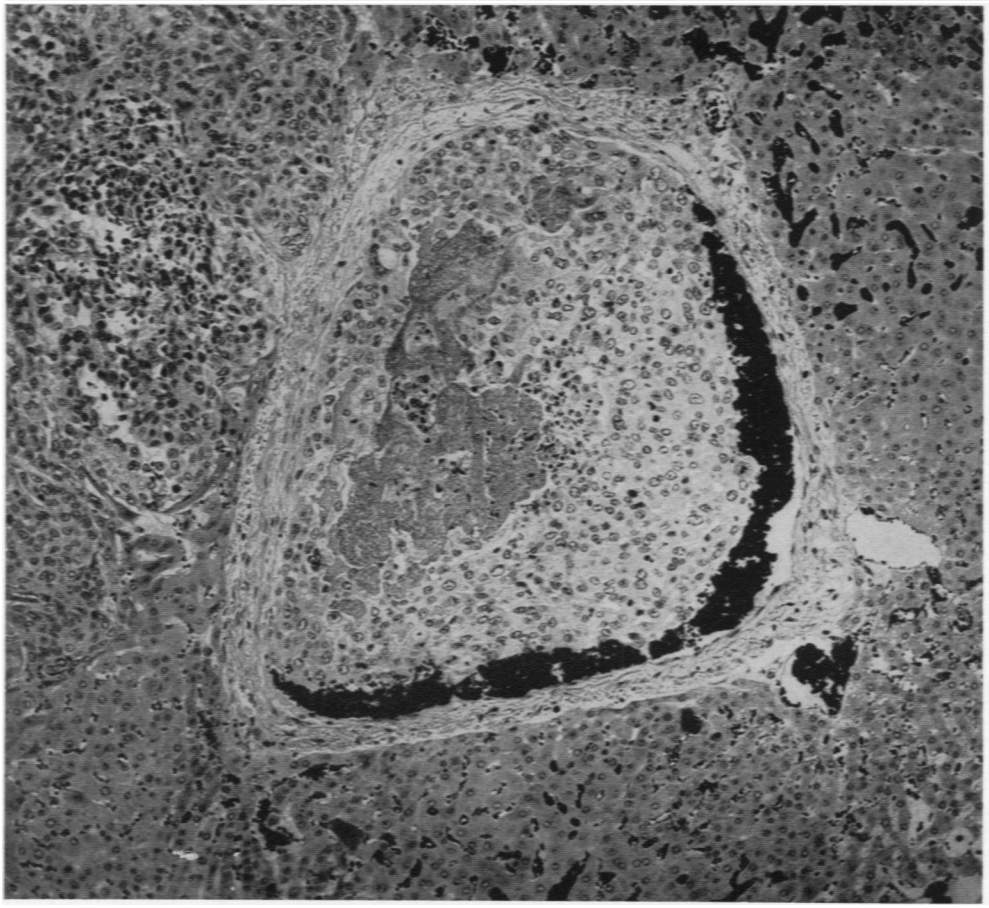

12